

## Correlative Assessment of Interdental and Interradicular Bone Loss in Horizontal and Vertical Bone Defects In Chronic Periodontitis: A Clinical and Radiographic Study

Dr Shreya Shetty., BDS, MDS<sup>1\*</sup>, Dr Othman Wali., BDS, MSc<sup>2</sup>, Dr Abdulaziz Maleh., BDS,

Dr Khalied Alharthi., BDS, Dr. Abdulrahman Mengash., BDS, Dr Irfan Adil., BDS, MDS<sup>3</sup>, Ms Khamrunissa Hussain Sheikh., M.Sc<sup>4</sup>

<sup>1</sup>FICOI, Associate professor, Dentistry program, IBN SINA National College of medical sciences, Jeddah, KSA, Saudi Arabia.

<sup>2</sup>Vice dean, Dentistry program, Swedish board certified in periodontology and dental implants, perio-prosth fellowship, IBN SINA, National college of medical sciences, Jeddah, KSA, Saudi Arabia.

<sup>3</sup>Assistant professor, Dentistry program, IBN SINA National College of medical sciences, Jeddah, KSA, Saudi Arabia.

<sup>4</sup>Quality assurance center, IBN SINA National College of medical sciences, Jeddah, KSA, Saudi Arabia.

**Abstract:** It is important to treat periodontitis before involvement of furcation areas because of their complex anatomy and difficulty of access. Literature confirms that it is difficult to accurately determine the relationship of the amount of bone loss in the interdental areas associated with the interradicular areas and correlate them with the clinical periodontal status. The aim of this study was therefore to assess the existence of such an association, if any, in subjects with chronic periodontitis. The threshold of alveolar bone loss associated with progression of periodontal destruction and involvement of interradicular areas of the furcations is not clearly defined in the literature. The aim of this study was to investigate a correlation, if any between interdental and interradicular bone loss and clinical parameters in patients with chronic periodontitis. Periapical (IOPA) radiographs of mandibular molars were obtained from 193 sites in 33 males and 21 females between the age group of 25 and 55 years having chronic periodontitis. These were then scanned and digital measurement of linear distances was performed using dicom software of height and width of defect (horizontal and vertical), bone defect angle and interradicular bone loss. These measurements were correlated to pocket depth (PD) and clinical attachment loss (CAL) using One-way ANOVA followed by Tukeys HSD post hoc tests. Bone height significantly correlated with probing depth and CAL in horizontal defects ( $p < 0.005$ ) with hardly any furcation involvement (1.55%) whereas both bone height and width showed significant correlation with probing depth and CAL in vertical defects ( $P < 0.001$ ) with nearly 77% of sites showing furcation defects. A strong correlation of clinical parameters with bone defect dimensions suggests that early diagnosis and management of interdental bone loss may be critical to prevent furcation involvement.

**Keyword:** Interdental bone, interradicular bone, furcation involvement, clinical attachment loss, probing depths

### \*Corresponding Author

DR SHREYA SHETTY\*, FICOI, Associate professor,  
Dentistry program, IBN SINA National College of medical  
sciences, Jeddah, KSA, Saudi Arabia.



Received On 18 October 2019

Revised On 23 November 2019

Accepted On 17 December 2019

Published On 03 January 2020

**Funding** This research did not receive any specific grant from any funding agencies in the public, commercial or not for profit sectors.

**Citation** \* DR SHREYA SHETTY, DR OTHMAN WALI., DR ABDULAZIZ MALEH, DR KHALIED ALHARTHI, DR. ABDULRAHMAN MENGASH, DR IRFAN ADIL, MS KHAMRUNISSA HUSSAIN SHEIKH, , Correlative Assessment Of Interdental And Interradicular Bone Loss In Horizontal And Vertical Bone Defects In Chronic Periodontitis: A Clinical And Radiographic Study.(2020).Int. J. Life Sci. Pharma Res.10(1). P 23-29 <http://dx.doi.org/ijlpr 2020; doi 10.22376/ijpbs/lpr.2020.10.1.P 23-29>

This article is under the CC BY- NC-ND Licence (<https://creativecommons.org/licenses/by-nc-nd/4.0>)  
Copyright @ International Journal of Life Science and Pharma Research, available at [www.ijlpr.com](http://www.ijlpr.com)



## I. INTRODUCTION

Reducing the risk of disease progression is one of the major goals of periodontal therapy.<sup>1</sup> Ongoing disease activity is difficult to ascertain clinically and the clinician usually relies on a combination of data from clinical examinations and radiographs to describe the amount of periodontal destruction that has already occurred and use it as a guide to assess disease progression and predict future tissue destruction. Radiographic diagnostic aids such as intraoral periapical radiographs, bitewings, and panoramic radiographs have been consistently used to determine bone loss in periodontal disease to enable accurate diagnosis<sup>2</sup> and plan appropriate treatment.<sup>3,4</sup> In addition, computer analysis of digital radiographic images is a very popular and fairly accurate method as the measurements are precise and are often used to characterize the amount of bone loss in osseous periodontal defects.<sup>3</sup> It is important to determine the extent of bony lesions in periodontal disease mainly to understand the possible outcomes of different regenerative procedures<sup>5,6,7</sup> and for correct periodontal risk assessment.<sup>8</sup> A radiograph is one such tool by which, periodontal hard tissue changes can be estimated with high specificity, especially in moderate forms of periodontitis.<sup>9,10</sup> One of the greatest challenges to the success of periodontal therapy is management of the furcation areas not only in terms of clinical examination and radiographic analysis due to their complex morphology but also due to increased severity and progression of disease which may also be enhanced due to limited accessibility.<sup>11</sup> Compromised treatment outcomes have been largely observed following management of furcation areas, regardless of the treatment modality employed.<sup>12</sup> Therefore, furcation defects represent formidable problems in the treatment of periodontal disease thus necessitating an early diagnosis and treatment. *Evidence shows that* There is evidence that interdental bone loss was found to be associated with progressive bone destruction in furcation area which suggests that early detection of interdental bone loss can be helpful in predicting future interradicular bone loss.<sup>11</sup> The threshold of alveolar bone loss associated with progression of periodontal destruction and involvement of interradicular (furcation) areas is not clearly defined in the literature. The need of a simple, less elaborate, time and cost-efficient diagnostic tool is required for careful comprehensive examination, diagnosis, and timely intervention of furcation lesions at their earliest, so that the best clinic outcomes can be achieved. The aim of this study was to investigate the correlation between clinical periodontal parameters, interdental bone dimensions, and interradicular bone loss (furcation involvement) in patients with chronic periodontitis so as to explore the potential of interdental bone loss as a rough approximate screening tool for early furcation diagnosis in molars.

## 2. MATERIALS AND METHODS

Following the approval of the Institutional Ethical committee of IBN SINA National College of Medical Sciences, Jeddah, KSA; and explaining the study to the subjects; a total of 220 patients were screened out of which; 193 sites in 33 males and 21 females (n=56) between the age group of 25 and 55 years having chronic periodontitis was diagnosed according to AAP guidelines were selected based on the following criteria:

1. Systemically healthy patients.

2. No history of smoking, tobacco chewing in any form or Para functional habits
3. Not physically or mentally challenged.
4. No history of drug intake (antibiotics, analgesics or others) in the last 6 months.
5. No history of any kind of periodontal treatment in the last 6 months.
6. Patients with bone loss (horizontal /vertical) and buccal furcation involvement in mandibular molars only.

The following parameters were measured:

### 2.1 Clinical Measurements

Probing depth- from the gingival margin to the base of the pocket. CAL (clinical attachment level) – from the CEJ (cemento-enamel junction) to the base of the pocket. Furcation involvement - Furcation involvement was assessed using a color coded, calibrated Naber's probe (PQ2N, Hu Friedy, Chicago, IL, USA), marked at 3-mm intervals according to Glickman's classification. Pocket depth (PD) and clinical attachment loss (CAL) were recorded clinically at 3 sites on the buccal aspect of the teeth to the nearest 0.5 mm using UNC-15 probe (Hu Friedy, Chicago, IL, USA).

### 2.2 Radiographic Measurements

One hundred-twenty (120) Periapical (IOPA) radiographs of mandibular molars were obtained by paralleling technique (long-cone technique/right-angle technique) using commercially available film holder, Skydent E speed films, USA exposed to long cone paralleling source, Gendex, 70kv, USA for 0.5 seconds and developed under standardized conditions to reduce the differences in brightness and contrast to a minimum. The radiograph was then scanned using a scanner with a resolution of 600 dots per inch to make it accessible to digital analysis. Digital measurement of linear distances was performed using a computer software program MicroDicom DICOM viewer 3.0.1 while viewing on a 17-inch screen. All radiographs were evaluated under 9.5-fold magnification and included the following measurements:

- Height of defect (BH)
- Width of defect (BW).
- Furcation involvement (inter radicular bone loss)

Prior to measuring the radiographs, the examiner was trained to identify the landmarks correctly, viewing 10 radiographs several times. Radiographic assessment included the following measurements:

Height of defect (H)( Figure 1 & 2): CEJ-AC: Cemento-enamel junction line to alveolar crest (in horizontal bone loss), CEJ-BD: Cemento-enamel junction line to apical extension of the bony defect (BD) (in angular bone loss). Width of defect (W) (Figure 1 & 2): Auxiliary line (AUX1) was drawn parallel to the long axis of the tooth. Auxiliary line (AUX2) was drawn perpendicular to the AUX1 through the most coronal extension of the lateral wall of the infrabony defect.

### 2.3 Bone defect width

Measured from the lateral margin of the infrabony defect to the point where AUX2 crosses the root surface.( angular defects) Measured between the interproximal areas of the

adjacent teeth at the level of the alveolar crest (horizontal defects)

**2.4 Furcation width**

The distance between the mesial and distal root on the level of the AC within the furcation.

**3. STATISTICAL ANALYSIS**

The data collected was divided into 2 groups comprising of horizontal and vertical defects. Each group was further

**4. RESULTS**

**4.1 Horizontal Bone Defects**

subdivided into subgroups based on pocket depths and CAL ;<3 mm and ≥ 3mm for horizontal defects; and < 3mm, = 3mm and >3mm for vertical defects. The various probing depths and CAL with the respective height and width of the bony defect were statistically analyzed using ANOVA followed by Tukeys HSD post hoc tests to further understand significant differences between them. One-way ANOVA was used to compare three different pocket depths and CAL with respect to the height and width at a particular site. This was followed by Tukeys HSD post hoc tests to know the significant difference between them.

**Table 1. Site distribution of the defects**

		Frequency	Percent	Valid Percent	Cumulative Percent
Valid	DB	52	45.2	45.2	45.2
	MB	63	54.8	54.8	100.0
Total		115	100.0	100.0	

Out of a total of 115 horizontal bone defects, 45% were on distobuccal sites and 55% on mesiobuccal sites.

**Table 2. Comparison of two different pocket depths to Height & Width of bone defect**

	Bone Weight		Bone Height	
	Mean	SD	Mean	SD
<3	3.7	3.76	2.76	0.88
≥3	3.5	2.79	3.18	0.98
t-value	0.269		-2.329	
p-value	0.768		0.02 significant	

**Table 3. Comparison of two different CAL to Height & Width of bone defect**

	Bone Weight		Bone Height	
	Mean	SD	Mean	SD
<3	3.54	3.4	2.84	0.88
≥3	4.65	3.9	3.38	0.38
t-value	-1.02		-1.83	
p-value	0.31		0.032 significant	

Comparative evaluation of various pocket depths and CAL to the bone width and height showed a significant Correlation between pocket depth and CAL ≥3mm with bone height only. (P<0.05)

**4.2 Vertical Defects**

**Table 4. Site distribution of the defects**

		Frequency	Percent	Valid Percent	Cumulative Percent
Valid	DB	12	15.4	15.4	15.4
	MB	66	84.6	84.6	100.0
Total		78	100.0	100.0	

Out of a total of 78 vertical bone defects, 15% were on distobuccal sites and 85% on mesiobuccal sites.

**Table 5. Comparison of three different pocket depths to Height & width of bone defect**

	Bone Width		Bone Height	
	Mean	SD	Mean	SD
< 3	3.38	1.23	3.22	1.26
= 3	3.25	1.09	3.92	1.13
>3	12.33	2.17	5.50	1.15
F-value	135.89		9.93	

p-value	0.000	0.000
<b>Pair wise comparison of pocket depths groups</b>		
Group <3	0.97	0.267
Group =3	0.000	0.000
Group >3	0.000	0.006

**Table 6. Comparison of two different CAL to Height & Width of bone defect**

	Bone Width		Bone Height	
	Mean	SD	Mean	SD
< 3	3.14	1.19	3.58	1.34
3-4	3.25	1.11	3.38	1.01
≥ 5	10.32	4.08	4.74	1.00
F-value	35.14		11.37	
p-value	0.000		0.000	
<b>Pair wise comparison of pocket depths groups</b>				
Group <3	0.99		0.889	
Group =3	0.00		0.001	
Group >3	0.00		0.000	

Comparative evaluation of various pocket depths and CAL to the bone width and height showed a significant Correlation between the various pocket depths and CAL with bone width and height (P<0.01).

**Table 7. Association Between Type Of Bone Loss And Furcation Involvement**

Bone Loss	Number Of Sites	Furcation Defects	Overall Percentage	Percentage Of Furcation Defects
Horizontal	115	03	1.55%	4.76%
Vertical	78	60	31.9%	95.24%
TOTAL	193	63	32.64%	100%

Overall, furcation defects were observed in 32.64% of the sites with defects of which 1.55% were horizontal defects and 31.9% were vertical defects. Of the 63 furcation defects, 4.76% were seen in horizontal bone loss and 95.24% in vertical bone loss.

**Table 8. Correlation Between Various Probing Depths, Cal, Bone Dimensions And Furcation Involvement**

PD	CAL	BH	BW	FURCATION
<2mm	<2mm	EQUAL(>3mm)	EQUAL(>3mm)	Present
<2mm	<2mm	LESS(<3mm)	MORE(>3mm)	Absent
>2mm but<3mm	>2mm but<3mm	EQUAL(<3mm)	EQUAL(<3mm)	Present
>3mm	>3mm	MORE(>3mm)	LESS(<3mm)	Absent
>3mm	>3mm	EQUAL(>3mm)	EQUAL(>3mm)	Present
>3mm	>3mm	LESS(>5mm)	MORE(>5mm)	Present

PD – probing depth, CAL – clinical attachment loss, BH- bone height, BW- bone width, Less, more and equal refer to comparison of bone height and width with each other

When the probing depths and CAL were correlated with the bone dimensions and furcation involvement, it was observed that when PD and CAL were less than 2 mm, two situations were found. When bone height and width of the defects were equal, furcation involvement was present. However, when the bone height was less and bone width was more, there was no furcation involvement. On the other hand, for PD and CAL between 2 and 3 mm, and equal bone height

and width, furcation involvement was observed. For PD and CAL greater than 3 mm, when the bone width was less and bone height was more, furcation involvement was absent. On the contrary, with equal bone height and width, furcation involvement was present. Similarly, even when the bone height was less but bone width was more, there was presence of furcation involvement.

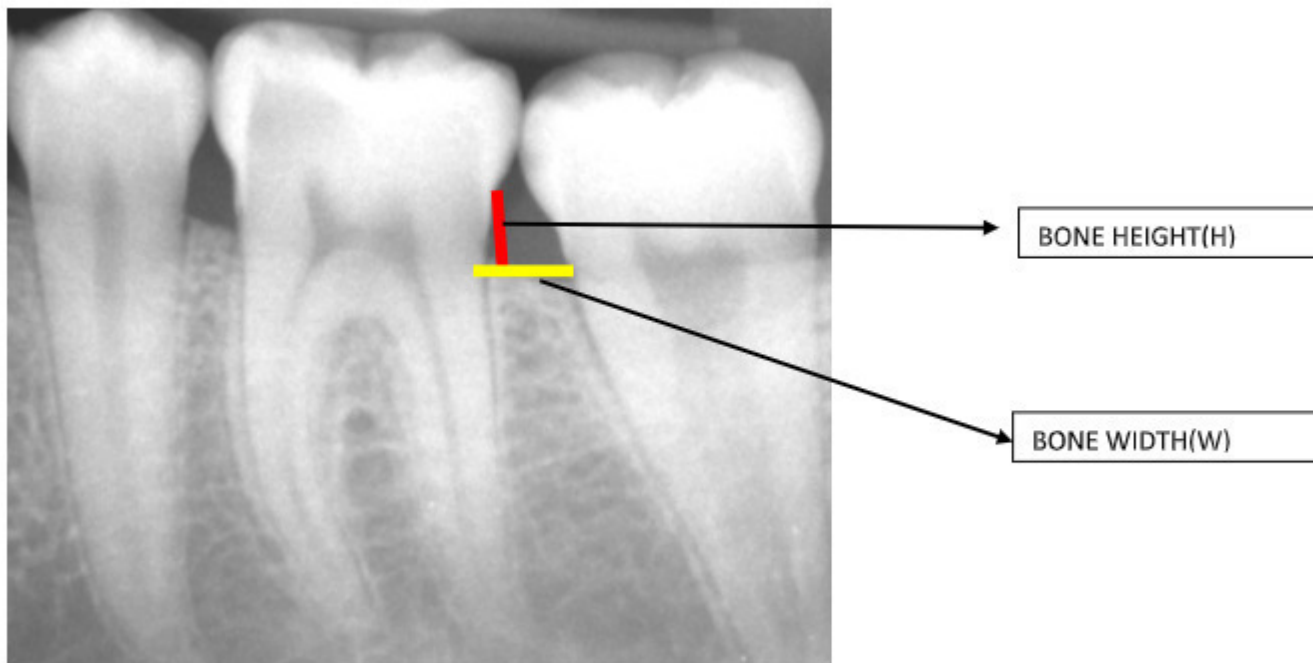


Fig 1. Horizontal Defects

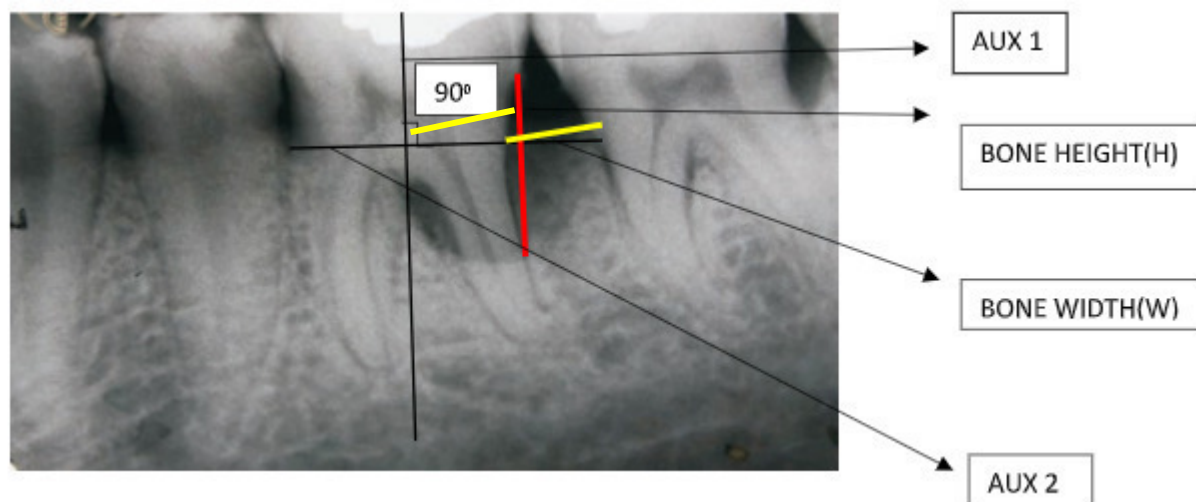


Fig 2. Vertical Defects

## 5 DISCUSSION

Diagnosis and management of periodontal diseases is largely dependent on clinical and radiographic assessments.<sup>13</sup> Radiographic measurements using reference points such as the CEJ (Cemento enamel junction), alveolar crest, etc are common. Involvement of furcation areas is often detected using both clinical and radiographic parameters. The complexity of the furcation, both in terms of disease progression and management is still an enigma faced by the periodontist most often today. Direct measurements from enlarged IOPAs<sup>14, 15</sup> or computer digitized images<sup>16,17</sup> have been studied abundantly. Ideally, there should not be differences when measurements are made from enlarged images or from digitized images.<sup>13</sup> But due to lack of standardization of radiographs and radiographic techniques, there may be unavoidable errors which may lead to inaccuracies in diagnosis and treatment planning. A digital radiographic software helps to minimize these errors providing close to accurate measurements. The computer software program (DICOM) used in the present study allowed measurements with good accuracy. In the present

study, IOPAs were preferred over OPGs as they are comparatively more accurate especially in the mandibular molar areas. This has been confirmed by Akesson et al who concluded that when OPG (Orthopantomogram) and IOPA radiograph measurements were compared with open surgery measurements<sup>9</sup>, OPG showed underestimation of bone loss ranging from 13–32% and were less accurate as compared with IOPA radiographs. Bone dimensions such as the height<sup>18</sup> and width<sup>19</sup> of the defect seem to influence the outcome of the treatment. Although it was not possible for us to clinically verify the height and width of the bone defect, we have compared the clinical probing depth measurements with radiographic defect height and width. We decided to use only mandibular teeth in our study as chances of radiographic measurements are better and maxillary molars may give erroneous readings of furcation due to superimposition of the palatal root. In our study, we found more of horizontal defects (115) compared to vertical defects (78) which is in accordance with a study by Jayakumar et al. in 2014 who reported that prevalence of horizontal type of bone loss (92.2%) was more common than vertical bone loss (7.8%). Additionally, a higher number of mesiobuccal sites compared

to distobuccal in horizontal (55%) and vertical defects (85%) was observed in our study. (Table 1 & 4) This is in contrast to the findings of the above author who found more mesial defects compared to distal.<sup>20</sup> With regard to the horizontal defects, there was a significant correlation with the clinical parameters and bone height only but not bone width which is obvious since increased probing depth correlates with attachment loss and increased bone loss as well. (table 2 & 3) In the vertical defects, there was a significant correlation with the clinical parameters and bone height and width. (table 5 & 6) This in accordance with the findings of Desai et al<sup>21</sup> who clearly showed that increased pocket depth causes increased amount of bone loss, which can be recorded as height and width of the defect on the radiographs. Interestingly the percentage of horizontal bone defects associated with furcation involvement was barely 1.55% of the total sites and 4.76% of the furcation defects observed in the study. On the contrary, nearly 32% of the sites with vertical defects showed furcation involvement amounting 95.24% of the furcation defects observed in the study. (table 7) This is in accordance with the findings of Vandana et al who observed that mandibular molars showed higher frequency of furcation involvement than maxillary molars but found to be statistically not significant.<sup>22</sup> On the other hand, it has also been reported that the maxillary molars showed higher frequency of furcation engagement than the mandibular molars.<sup>23</sup> When the clinical parameters of probing depth and CAL were compared to the bone height and width and furcation involvement, it was observed that the bone dimensions may have a correlation with the presence or absence of furcation. Probing depths and CAL greater than 3mm having equal bone height and width greater than 3 mm definitely showed presence of furcation involvement. (table 8) It is obvious that the bone width of interradicular bone defect is the key to determine the involvement of the furcation area. Larger bone widths lost most probably increase the likelihood of lateral spread of the periodontal infection to the furcation areas. In very few sites, clinical parameters less than 2mm and between 2-3 mm also showed the presence of furcation involvement with equal width and height of bone, either less than or greater than 3mm. (table 8) These variations may be attributed to the anatomy of the interdental and furcation areas. However, bone height may not be such a key determinant as increasing bone height in a defect clearly indicates spread of infection in a vertical direction towards the periapical area sparing the furcation but retrograde spread may be possible. These associations may be useful to determine the risk of involvement of the furcation area during progression of periodontal disease. This correlation also strongly suggests that treatment of interdental bone destruction with different modalities can help to prevent furcation involvement but this again may depend to some extent on the root trunk length and

furcation anatomy. Several studies have found associations between interproximal bone loss and interradicular bone loss (furcation involvement)<sup>11,15,21,24</sup> but not many have included clinical parameters in their correlations. Clinical measurements may indeed not always provide a true picture of the periodontal situation nevertheless, combining and superimposing readings of probing and radiographs, can provide valuable information about periodontal hard and soft tissues<sup>2</sup> and assist in arriving at a periodontal diagnosis and in developing a comprehensive treatment plan. As is evident from the observations of our study, clinical measurements combined with radiographic parameters may provide an early insight into the interradicular area and may help in preventing the spread of periodontal infection. Use of digital radiography enhances the accuracy of measurement. One of the major limitations of the study was that only basic measurements were included in the radiographic parameters. Some more values such as bone defect angle, root trunk length and furcation width would have added more weightage to the correlation; which has been planned in the next leg of the study.

## 6 CONCLUSION

Clinical periodontal measurements and radiographic interdental bone loss may serve to predict the periodontal condition of the furcation area in the early stages of the disease which may enable the clinician to prevent the disease progression as well enhance therapeutic outcomes in these areas of complex morphology.

## 7 AUTHORS CONTRIBUTION STATEMENT

Dr. Shreya Shetty conceptualized the idea of the study and also the main author of the manuscript. Dr. Othman Wali was responsible for the necessary permissions for collection of data and he also supervised the execution of the study and gave valuable inputs throughout the duration of the study including revising the manuscript. Dr. Abdulaziz, Dr. AbdulRahman and Dr. Khaleid were fully responsible for managing the collection, entry and processing of the data especially related to the conversion of raw data into the digital software as well as the interpreting the output from the software to enable statistical analysis. Dr. Irfan was the key guide for radiological data interpretation and gave strategic inputs in the manuscript wherever necessary. Ms. Khamarunissa was the statistician for this study and the entire data with the interpretation which is in the results part of the manuscript can be credited to her.

## 8 CONFLICT OF INTEREST

Conflict of interest declared none.

## 9 REFERENCES

1. Page RC, Beck JD. Risk assessment for periodontal diseases. *Int Dent J*. 1997;47(2):61-87. DOI: 10.1111/j.1875-595X.1997.tb00680.x
2. Bragger U. Radiographic parameters: biological significance and clinical use. *Periodontol* 2000. 2005;39(1):73-90. DOI: 10.1111/j.1600-0757.2005.00128.x
3. Mol A. Imaging methods in periodontology. *Periodontol* 2000. 2004;34(1):34-48. DOI: 10.1046/j.0906-6713.2003.003423.x
4. Wennstrom JL, Papapanou PN, Grondahl K. A model for decision making regarding periodontal treatment needs. *J Clin Periodontol*. 1990;17(4):217-22. DOI: 10.1111/j.1600-051X.1990.tb00016.x
5. Eickholz P, Horr T, Klein F, Hassfeld S, Kim TS. Radiographic parameters for prognosis of periodontal healing of infrabony defects: Two different definitions of defect depth. *J Periodontol*. 2004;75(3):399-407. DOI: 10.1902/jop.2004.75.3.399

6. Ti-Sun K, Knittel M, Dörfer C, Steinbrenner H, Holle R, Eickholz P. Comparison of two types of synthetic biodegradable barriers for GTR in interproximal infrabony defects: clinical and radiographic 24-month results. *International Journal of Periodontics & Restorative Dentistry*. 2003;23(5):480-89.
7. Windisch P, Sculean A, Klein F, Toth V, Gera I, Reich R, et al. Comparison of clinical, radiographic and histometric measurements following treatment with guided tissue regeneration or enamel matrix proteins in human periodontal defects. *J Periodontol*. 2002;73(4):409-17. DOI: 10.1902/jop.2002.73.4.409
8. Lang NP, Tonetti MS. Periodontal risk assessment (PRA) for patients in supportive periodontal therapy (SPT). *Oral Health Prev Dent*. 2003;1(1):7-16. Available from: [http://periodontools.com/pdf/Lang\\_&\\_Tonetti\\_2003.pdf](http://periodontools.com/pdf/Lang_&_Tonetti_2003.pdf)
9. Akesson L, Hakansson J, Rohlin M. Comparison of panoramic and intraoral radiography and pocket probing for the measurement of the marginal bone level. *J Clin Periodontol*. 1992;19(5):326-32. DOI: 10.1111/j.1600-051X.1992.tb00654.x
10. Hammerle CH, Ingold HP, Lang NP. Evaluation of clinical and radiographic scoring methods before and after initial periodontal therapy. *J Clin Periodontol*. 1990;17:255-63. DOI: 10.1111/j.1600-051X.1990.tb00022.x
11. Batra P, Das S, Jain S. Correlation of radiovisuographic analysis of interdental and interradicular bone loss in furcation involvement of mandibular first molars: A retrospective study. *Indian J Dent Res*. 2018;29:329-32. Available from: <http://www.ijdr.in/article.asp?issn=0970-9290;year=2018;volume=29;issue=3;spage=329;epage=332;aulast=Batra>
12. Al-Shammari KF, Kazor CE, Wang HL. Molar root anatomy and management of furcation defects. *J Clin Periodontol* 2001;28:730-40. DOI: 10.1034/j.1600-051x.2001.280803.x
13. Zybutz M, Rapoport D, Laurell L, Persson GR. Comparisons of clinical and radiographic measurements of inter-proximal vertical defects before and 1 year after surgical treatments. *J Clin Periodontol* 2000;27(3):179-86. DOI: 10.1034/j.1600-051x.2000.027003179.x
14. Persson RE, Hollender LG, Persson GR. Assessment of alveolar bone levels from intraoral radiographs in subjects between ages 15 and 94 years seeking dental care. *J Clin Periodontol*. 1998;25(8):647-54. DOI: 10.1111/j.1600-051X.1998.tb02501.x
15. Papapanou PN, Wennstrom JL. A 10-year retrospective study of periodontal disease progression. Clinical characteristics of subjects with pronounced and minimal disease development. *J Clin Periodontol*. 1990;17(2):78-84. DOI: 10.1111/j.1600-051X.1990.tb01066.x
16. Jeffcoat MK, Reddy MS, Magnusson I, Johnson B, Meredith MP, Cavanaugh PF Jr, et al. Efficacy of quantitative digital subtraction radiography using radiographs exposed in a multicenter trial. *J Periodontol Res*. 1996;31(3):157-60. DOI: 10.1111/j.1600-0765.1996.tb00478.x
17. Falk H, Laurell L, Ravald N, Teiwik A, Persson R. Guided tissue regeneration therapy of 203 consecutively treated intrabony defects using a bioresorbable matrix barrier. Clinical and radiographic findings. *J Periodontol* 1997;68(6):571-81. DOI: 10.1902/jop.1997.68.6.571
18. Cortellini P, Carnevale G, Sanz M, Tonetti MS. Treatment of deep and shallow intrabony defects. A multicenter randomized controlled clinical trial. *J Clin Periodontol*. 1998;25(12):981-7. DOI: 10.1111/j.1600-051X.1998.tb02402.x
19. Cortellini C, Tonetti MS. Radiographic defect angle influences the outcome of GTR therapy in intrabony defects. *J Dent Res*. 1999;78:2208.
20. Jayakumar, A., Rohini, S., Naveen, A., Haritha, A., & Reddy, K. (2010). Horizontal alveolar bone loss: A periodontal orphan. *Journal of Indian Society of Periodontology*. 2010;14(3):181. DOI: 10.4103/0972-124X.75914
21. Desai SR, Shinde HH. Correlation of interdental and interradicular bone loss in patients with chronic periodontitis: A clinical and radiographic study. *Niger J Clin Pract*. 2012;15(2):125-31. Available from: <https://www.ajol.info/index.php/njcp/article/view/78813>
22. Vandana KL, Lakhani N, Naveen kumar PG. Radiographic Evaluation of Periodontal Osseous Defects-A Retrospective Study. *Saudi J. Oral. Dent. Res*. 2017;2(1):18-21. Available from: [https://pdfs.semanticscholar.org/3626/b259304a2fda11484ec5708254c8e452894a.pdf?\\_ga=2.141861874.1766032802.1575883816-549517046.1570778030](https://pdfs.semanticscholar.org/3626/b259304a2fda11484ec5708254c8e452894a.pdf?_ga=2.141861874.1766032802.1575883816-549517046.1570778030)
23. Svärdröm, G., & Wennström, J. L. Prevalence of furcation involvements in patients referred for periodontal treatment. *Journal of clinical periodontology*. 1996;23(12):1093-9. DOI: 10.1111/j.1600-051X.1996.tb01809.x
24. Popova C, Mlachkova A, Emilov D. Correlation of interdental and interradicular bone loss- radiographic assessment. *J IMAB Ann Proc (Scientific Papers)*. 2008;2:35-7.